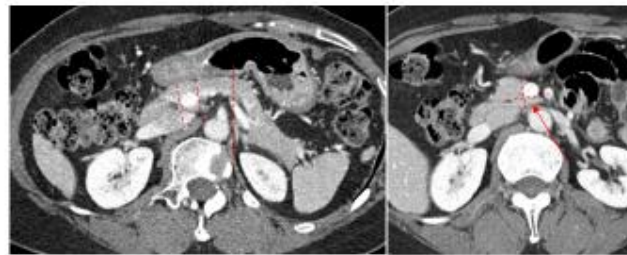
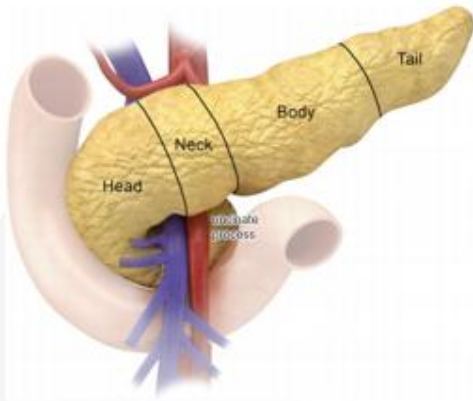


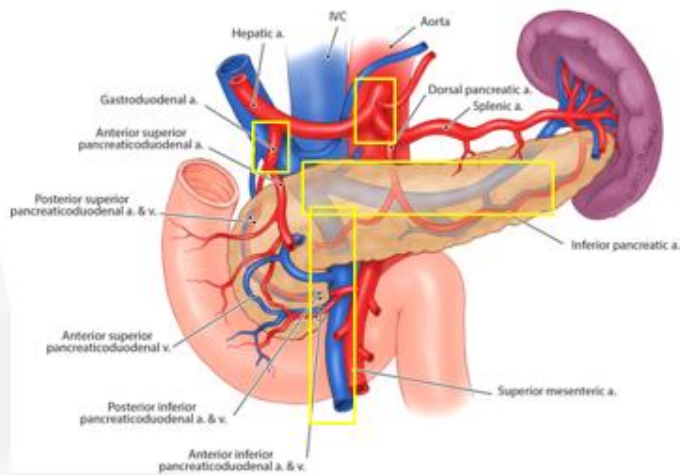
# KSUM 2026 Lecture syllabus

## Normal Anatomy of Pancreas



Anatomy and Embryology of the Pancreatic Gland. In: Sakr M, Stittes S. *Textbook of Pancreatic Cancer*. Springer

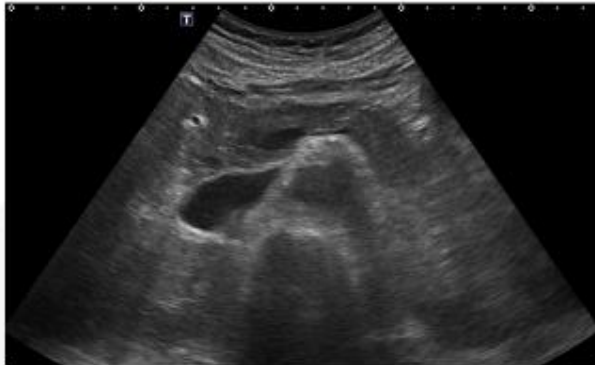
## Normal Anatomy of Pancreas



Pancreas. In: Skandalakis LJ. *Rectal Surgical Anatomy and Technique*. Springer

## How to scan pancreas

---



Transverse scan at epigastrium with tilting, upward to downward.

## What to see?

---



P-duct dilatation

Focal lesion detection

Cystic lesion follow up

USG guided procedure

## Normal Anatomy of Spleen

---

- Normal size (Korean; with CT)
  - Volume: 161 cm<sup>3</sup>
  - Weight: 174g
  - Height: 8cm
  - Decreases with aging
  - M>F, positive correlation with body height



## US of normal spleen

---

- Echogenicity: Homogeneous, spleen>liver, kidney
- Splenomegaly > 12cm, longitudinal coronal oblique plane

